

PRESCAPULAR MASS IN A CAT WITH ATYPICAL CIRCULATING CELLS

Guzera M.^{1,2}, Balcerzak J.³, Romańska M.³, Hoffmann I.²

¹ LABOKLIN Polska, Warsaw, Poland

² LABOKLIN, Bad Kissingen, Germany

³ Veterinary Practice Kochanowskiego, Warsaw, Poland

Signalment

Cat, 7 years old, male neutered, Domestic Shorthair.

History

The cat presented for an oncology consultation with a one year history of mild nonregenerative anaemia, neutropenia and the presence of occasional atypical cells on the blood smear. Presence of a mass of unknown duration in the right prescapular area was also reported. The cat was FeLV positive. No other clinical signs were reported. Lymphoma was suspected based on the clinical picture.

Clinical findings

Moderate right prescapular lymphadenopathy was present on physical examination. The cat was otherwise well in himself and did not exhibit any other signs of illness.

Diagnostic procedures

Complete blood count was performed on Sysmex XT-2000iV analyser and a peripheral blood smear was examined. Haematology revealed marked neutropenia ($0.98 \times 10^9/L$, reference interval, RI: $3-11 \times 10^9/L$) and the presence of atypical cells ($9.29 \times 10^9/L$). Automated platelet count was within reference intervals ($271 \times 10^9/L$, RI: $180-550 \times 10^9/L$). There were 21 nucleated red blood cells / 100 leukocytes. The most relevant blood smear features are demonstrated in Figure 1 and 2. Biochemistry showed no abnormalities except mild hyperglycaemia (7.88 mmol/L, RI: 5.55-7.22 mmol/L)

Fine-needle aspiration cytology (FNAC) of the right prescapular lymph node was performed (Figure 3-5).

Abdominal ultrasound was performed and showed an enlarged spleen of mixed echogenicity and lymphadenopathy of the mesenteric lymph nodes.

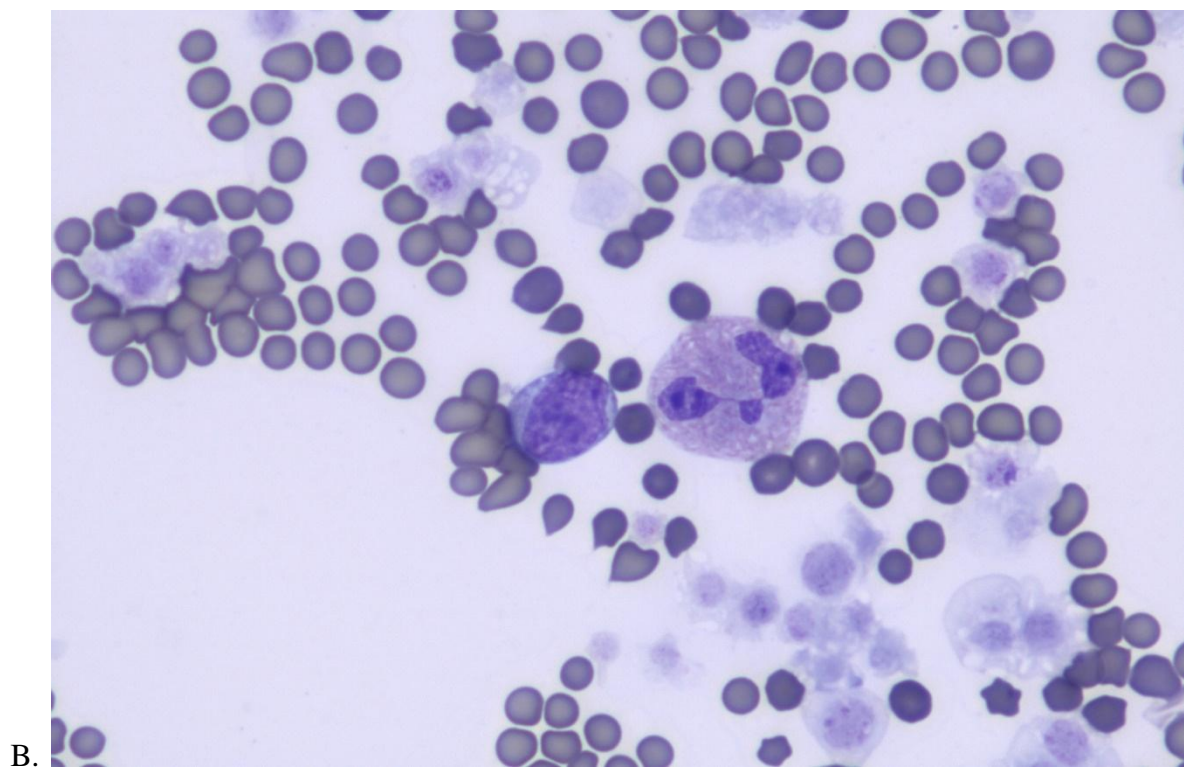
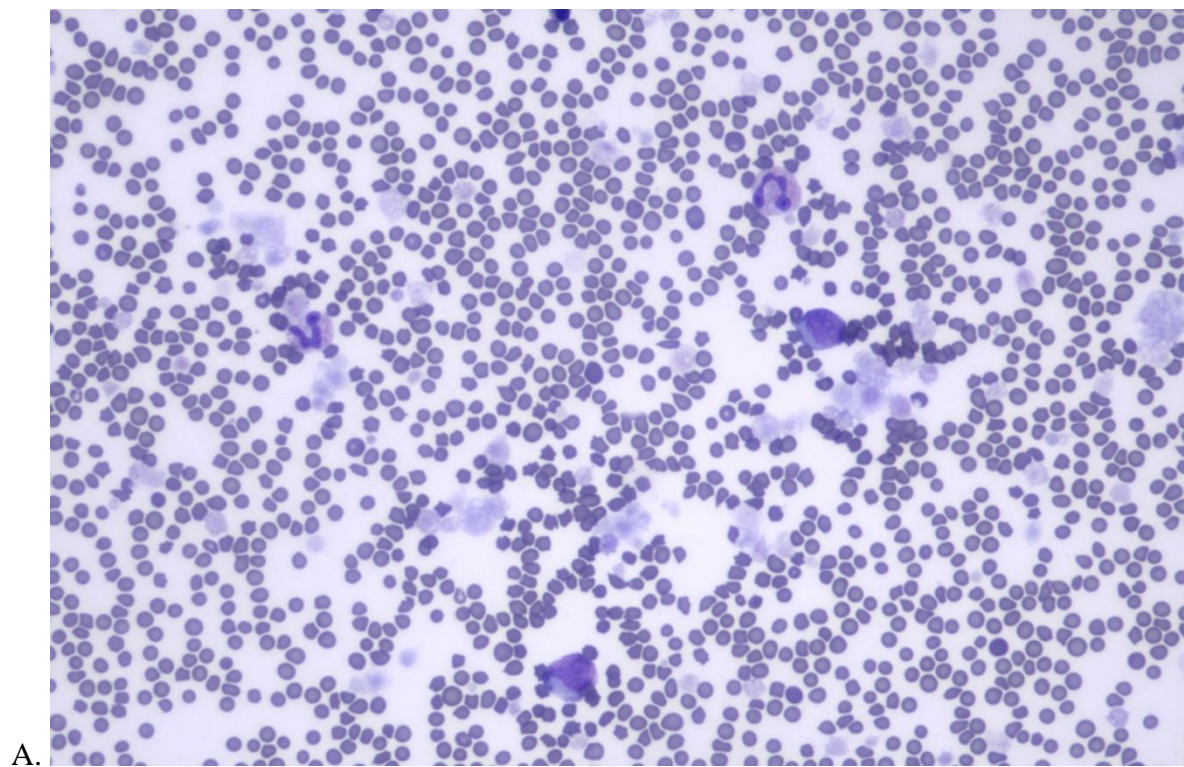


Figure 1. Peripheral blood smear from a 7 years old, male neutered, Domestic Shorthair cat. Hemacolor stain, 20x objective (A) and 50x objective (B).

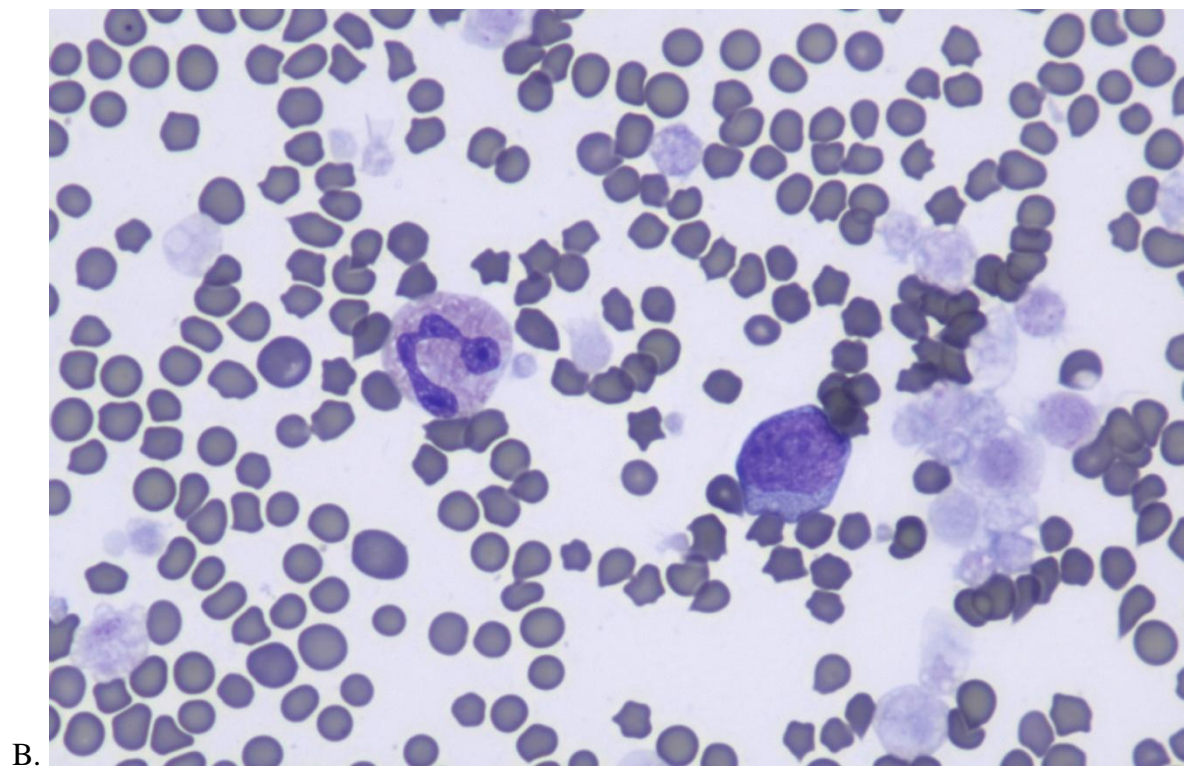
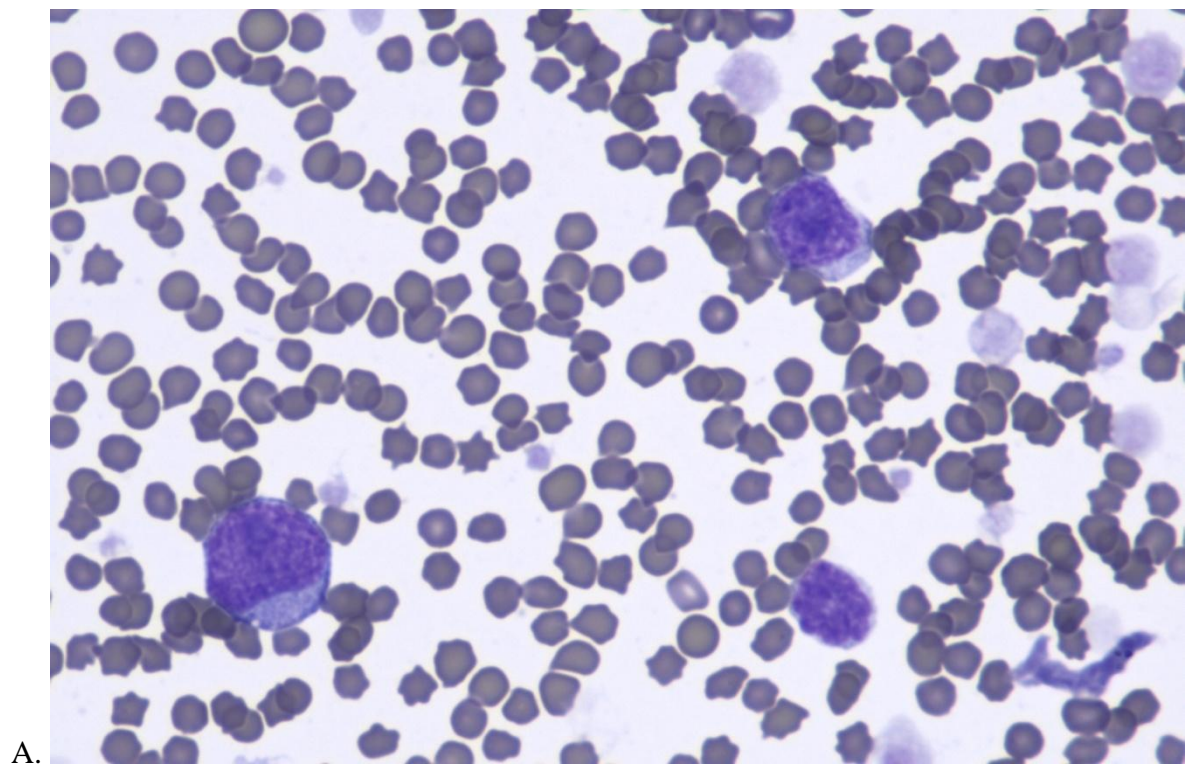


Figure 2. Peripheral blood smear from a 7 years old, male neutered, Domestic Shorthair cat. Hemacolor stain, 50x objective.

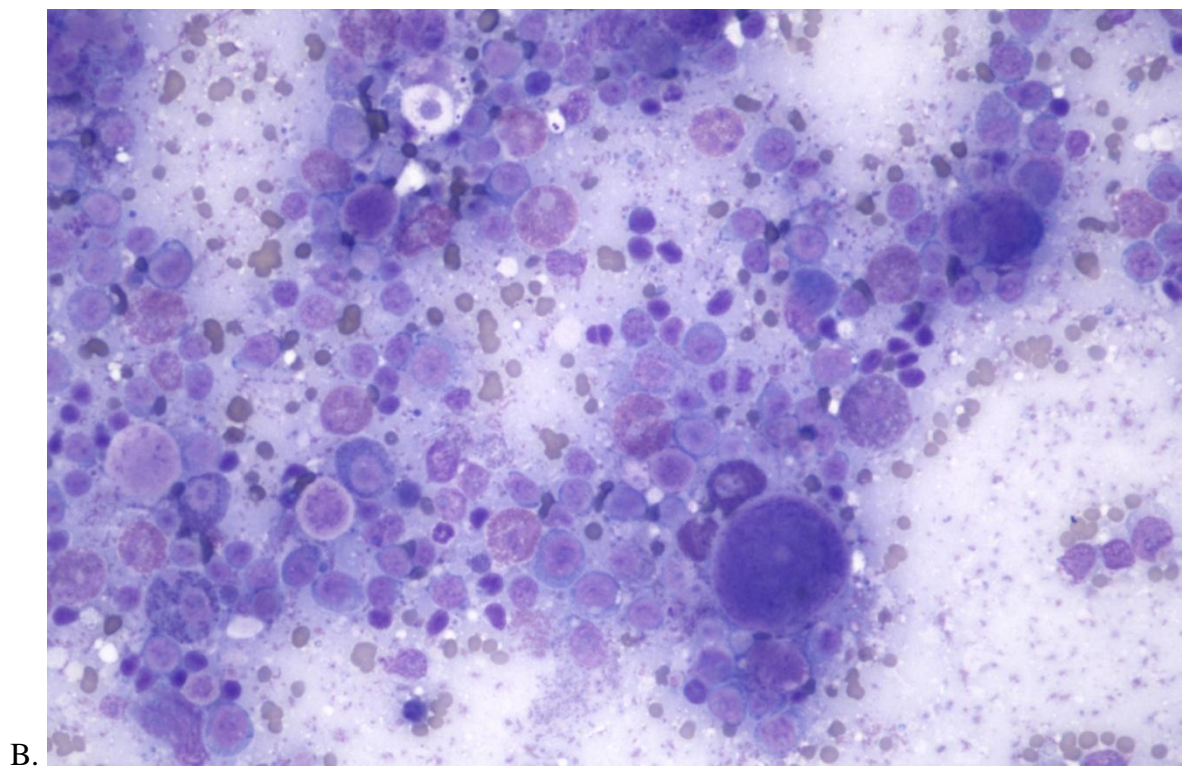
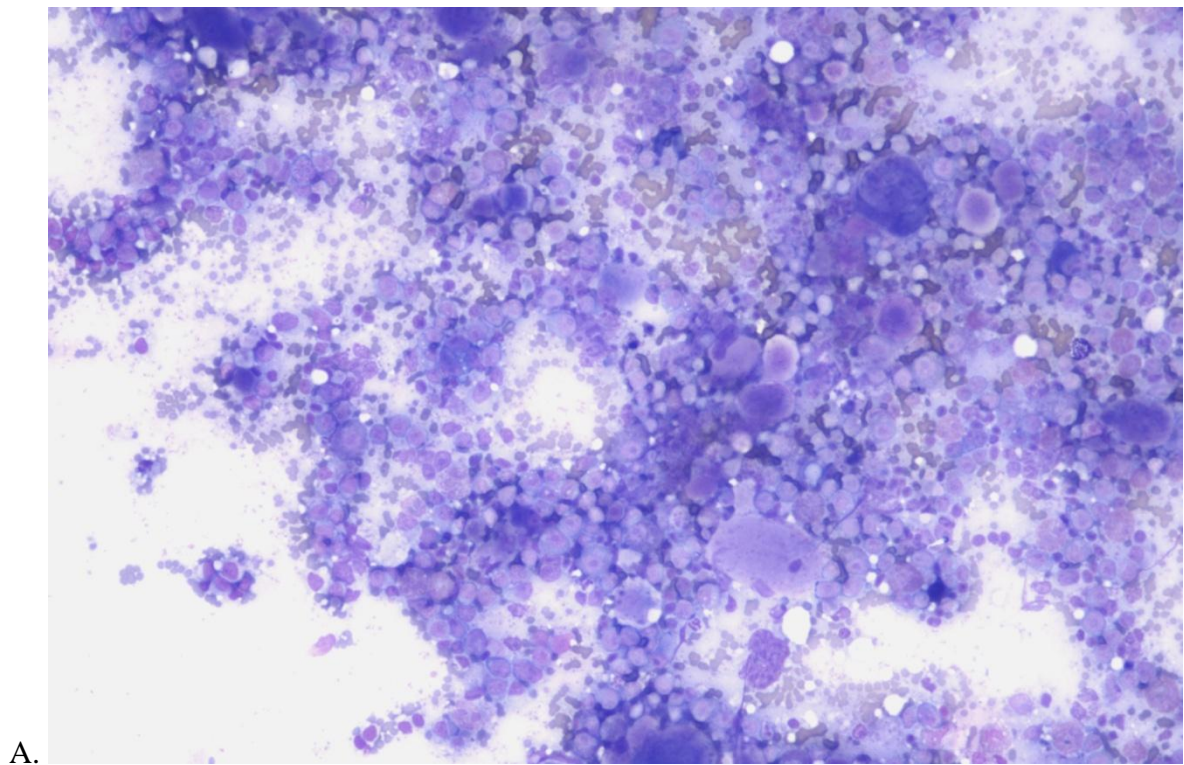


Figure 3. Fine-needle aspiration cytology of the prescapular lymph node from a 7 years old, male neutered, Domestic Shorthair cat. Hemacolor stain, 10x objective (A) and 20x objective (B).

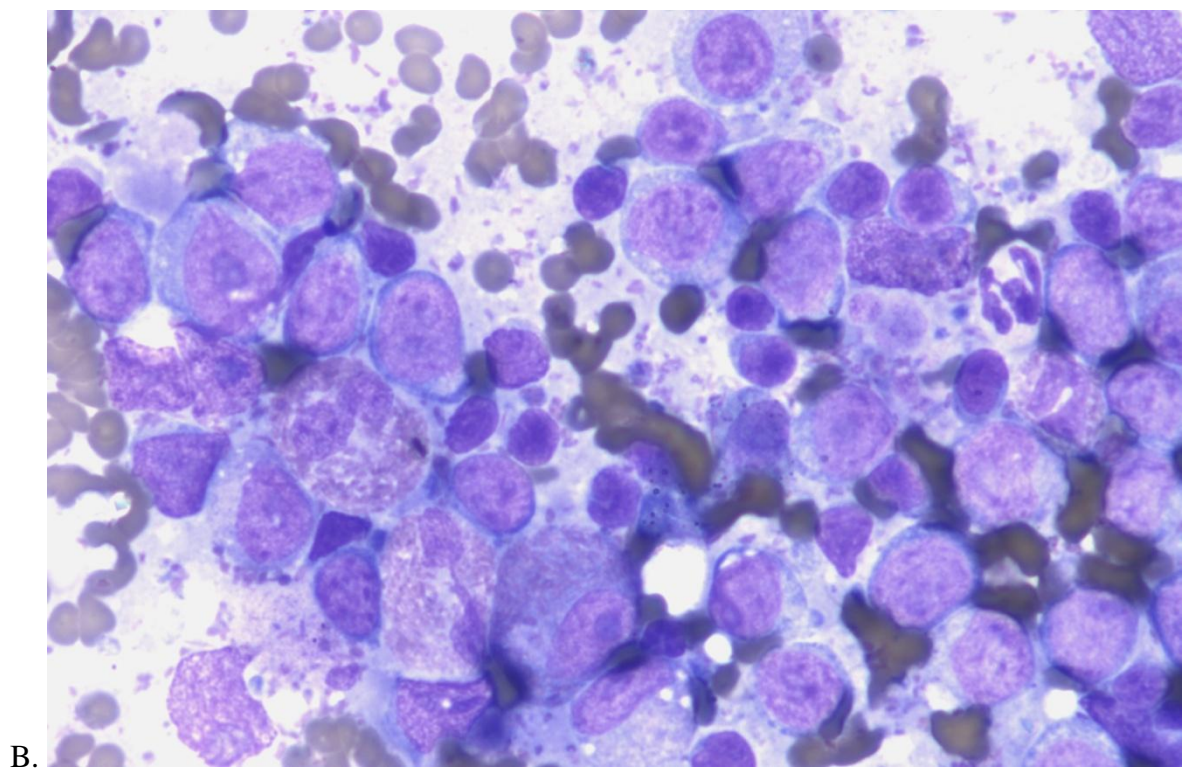
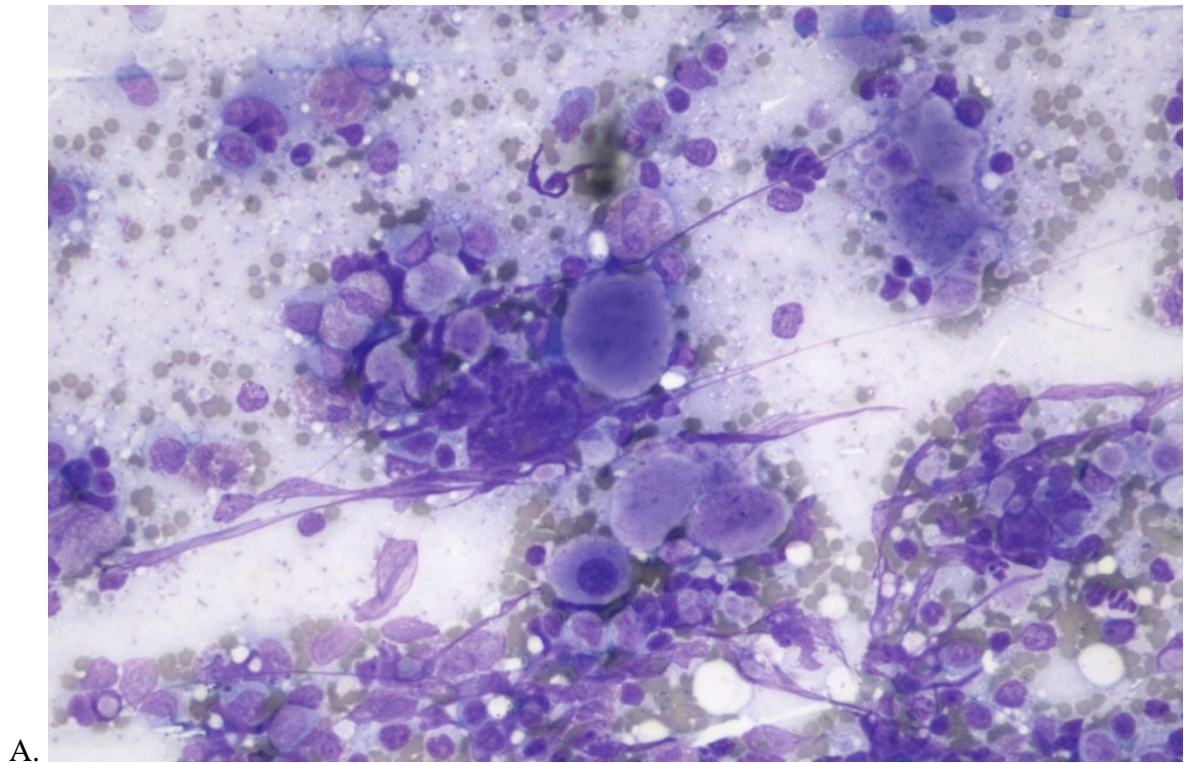


Figure 4. Fine-needle aspiration cytology of the prescapular lymph node from a 7 years old, male neutered, Domestic Shorthair cat. Hemacolor stain, 20x objective (A) and 50x objective (B).

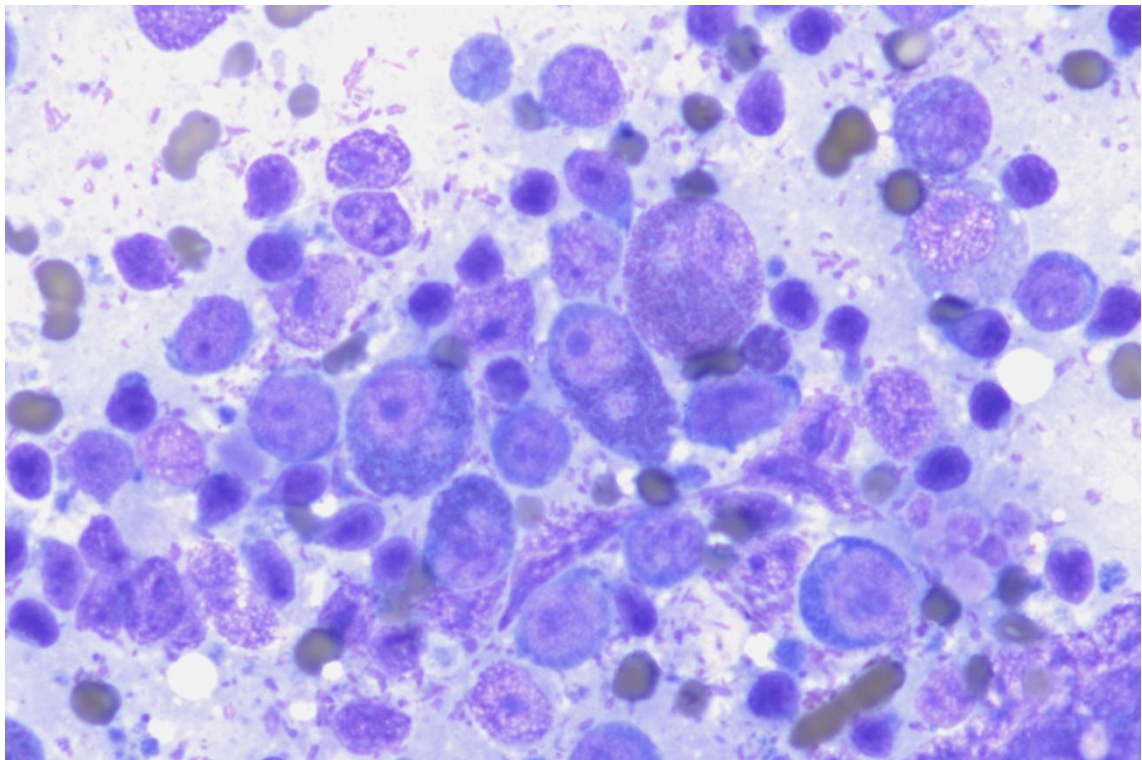


Figure 5. Fine-needle aspiration cytology of the prescapular lymph node from a 7 years old, male neutered, Domestic Shorthair cat. Hemacolor stain, 50x objective.

QUESTIONS:

- 1. What is your description of blood smear findings?**
- 2. What is your cytological description?**
- 3. What is your interpretation of the haematology and cytology findings and what further tests would you recommend?**