Leukocytosis in a dog

[1]Lukacs R.M., [2]Mastrorilli C., [3]Langston A., [2]Welles E.G.

[1] Department of Veterinary Clinical Sciences, University of Bologna, Italy

[2] Department of Pathobiology, Auburn University, AL, USA

[3] Dykes Veterinary Clinic, Foley, AL, USA

Signalment:

8 year old, female spayed, mixed breed dog.

History and Diagnostic procedures:

The dog was presented to an external clinic for anorexia approximately one month before contacting Auburn University Clinical Pathology Laboratory (AUCPL).

At the external clinic three complete blood counts (CBCs) were performed over a three week period, which showed marked and progressively increasing leukocytosis with neutrophilia. The clinic used an impedance hematology analyzer (Abaxis VetScan HM5 Hematology System, Abaxis North America, Union City, CA, USA).

The differential diagnoses for extreme neutrophilia includes severe inflammatory processes (e.g., peritonitis, pleuritis, pyometra, abscess), certain infectious agents (e.g., *Hepatozoon americanum*, *Ehrlichia canis*, *Rickettsia rickettsii*, *Babesia canis*), neutrophilia associated with a neoplastic proliferation or granulocytic leukemia. Pyometra can be ruled out because this dog is spayed. Pleuritis, peritonitis and abscess can be ruled out or confirmed with diagnostic imaging and cytological evaluation of effusion if present. Infectious agents could be ruled out or confirmed using serology tests or PCR and in some cases reviewing a peripheral blood smear. Granulocytic leukemia and paraneoplastic neutrophilia associated with cancer are diagnosed by exclusion of all other causes of neutrophilia.

Table 1: Patient CBC data from HM5.

Analyte	Patient day 1	Patient day 7	Patient day 11	Patient day 21	Reference interval
RBC (/µL)	4,860,000	5,010,000	4,960,000	4,990,000	5,500,000-8,500,00
Hgb (g/dL)	11.7	13.2	14.2	14.1	12-18
Hct (%)	34.98	36.2	34.6	35.2	37-55
MCV (fL)	72	72	70	70	60-77
MCHC (g/dL)	33.4	36.5	41.1	40	31-34
WBC (/µL)	74,090	135,500	153,600	---	6,000-17,000
Neutrophils (/µL)	65,890	108,700	124,300	---	3,000-12,000
Lymphocytes (/µL)	5,330	12,890	12,520	---	1,000-4,800
Monocytes (/µL)	460	11,720	15,530	---	200-1,500
Eosinophils (/µL)	1,570	1,560	1,590	---	0-800
Basophils (/µL)	830	640	680	---	0-400
Platelets (/µL)	485,000	376,000	390,000	388,000	200,000-500,000

--- no values were provided by the HM5 because the total WBC of the patient exceeded the maximum reportable value.

Figure 1: Example patient CBC report (day 7) from impedance hematology instrument with histogram.

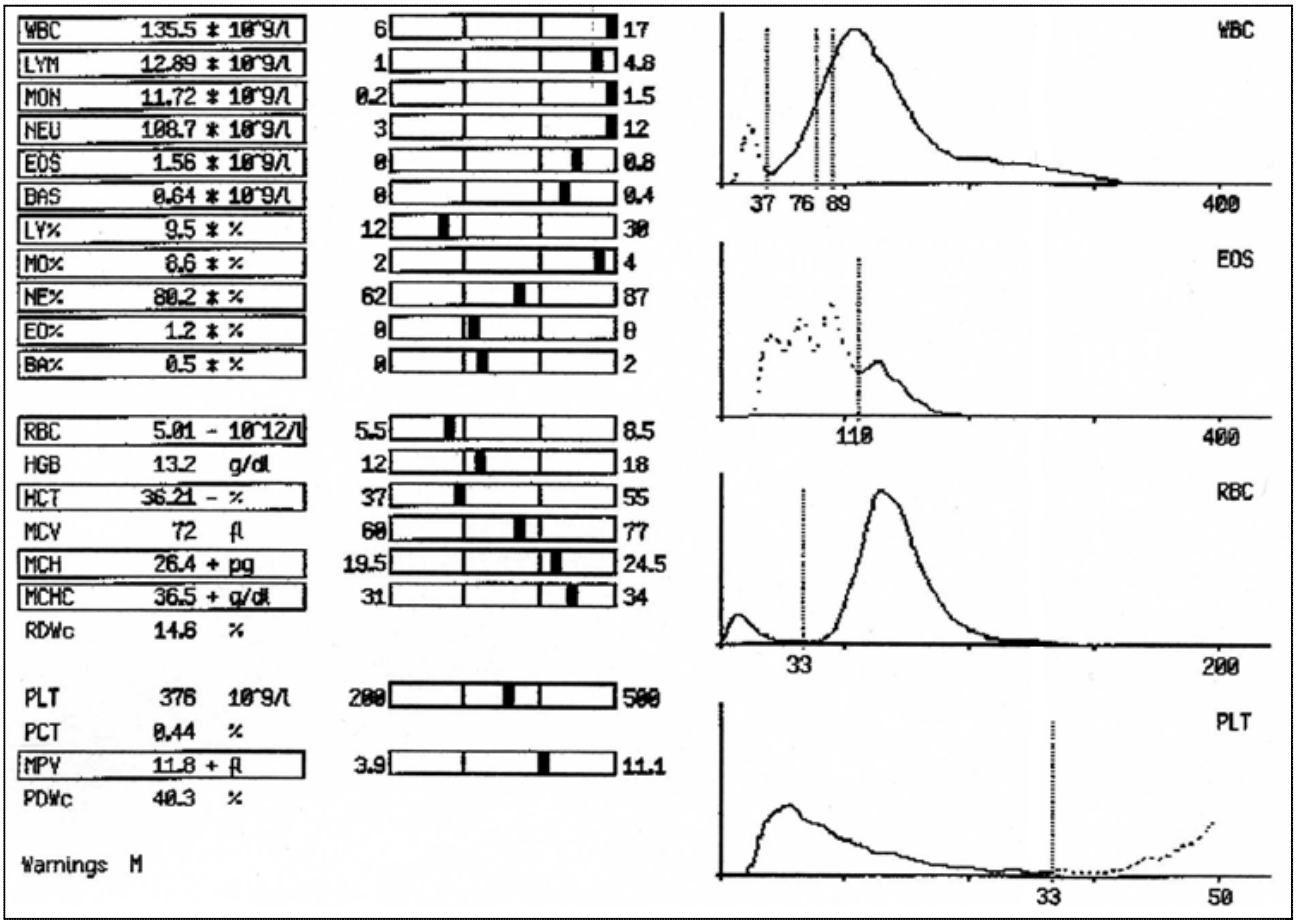

After three CBCs with progressively increasing total WBC the leukocytosis worsened and the impedance analyzer could not give a value for the white blood cells (total WBC exceeded the maximum reportable value for HM5). A peripheral blood sample and the patient's hematology reports (Table 1 and Figure 1) performed with the impedance hematology analyzer were submitted to the AUCPL. At AUCPL, a CBC using a flow-cytometry analyzer (ADVIA 120, Siemens Healthcare Diagnostics, Deerfield, IL, USA; software version 3.1.8.0-MS) was performed and a peripheral blood smear was examined (Table 2, Figures 2-5).

Table 2: Patient CBC data from ADVIA 120 hematology instrument and manual differential leukocyte counts.

Analyte	Patient's value	Reference interval
RBC (/µL)	4,600,000	6,020,000 – 8,640,000
Hgb (g/dL)	11.3	13.1 – 20.1
Hct (%)	37.6	38.7 – 59.2
MCV (fL)	81.8	60.5 – 73.8
MCH (pg)	24.6	20.4 – 25.7
MCHC (g/dL)	30.0	32 – 37.2
WBC (/µL)	164,700	5,090 – 17,410
Neutrophils (/µL)	29,800	2,600 – 10,400
Lymphocytes (/µL)	53,500	390 – 6,730
Monocytes (/µL)	4,700	160 – 1,160
Eosinophils (/µL)	900	12 – 1,160
Basophils (/µL)	1,800	rare
Platelets (/µL)	280,000	152,000 – 518,000

Figure 2: Peroxidase cytogram from ADVIA 120 hematology analyzer

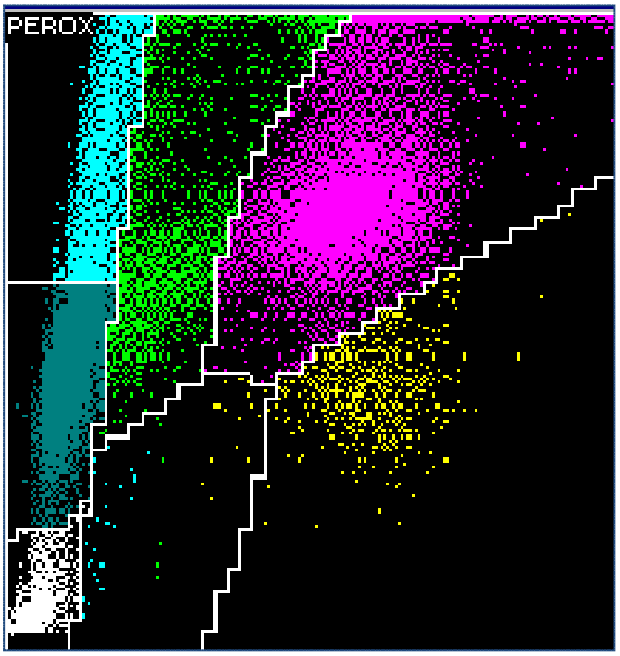

Figure 3: Basophil cytogram from ADVIA 120 hematology analyzer

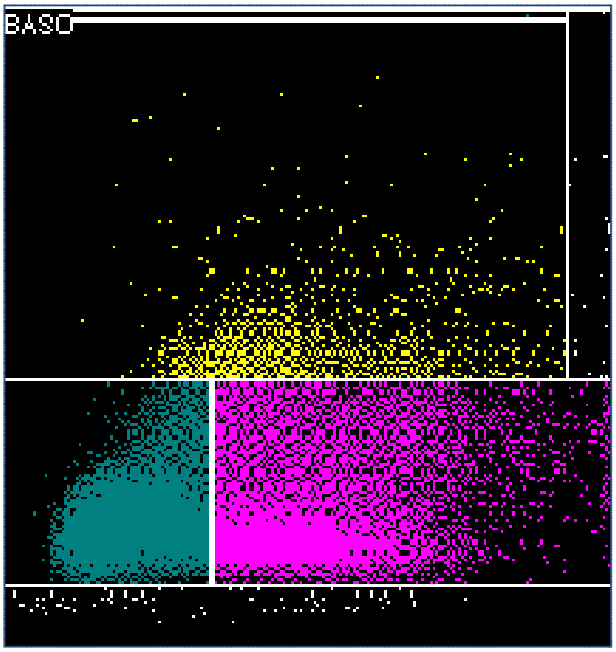

Figure 4: Peripheral blood smear, modified Wright's stain, 10x objective; shows extreme leukocytosis

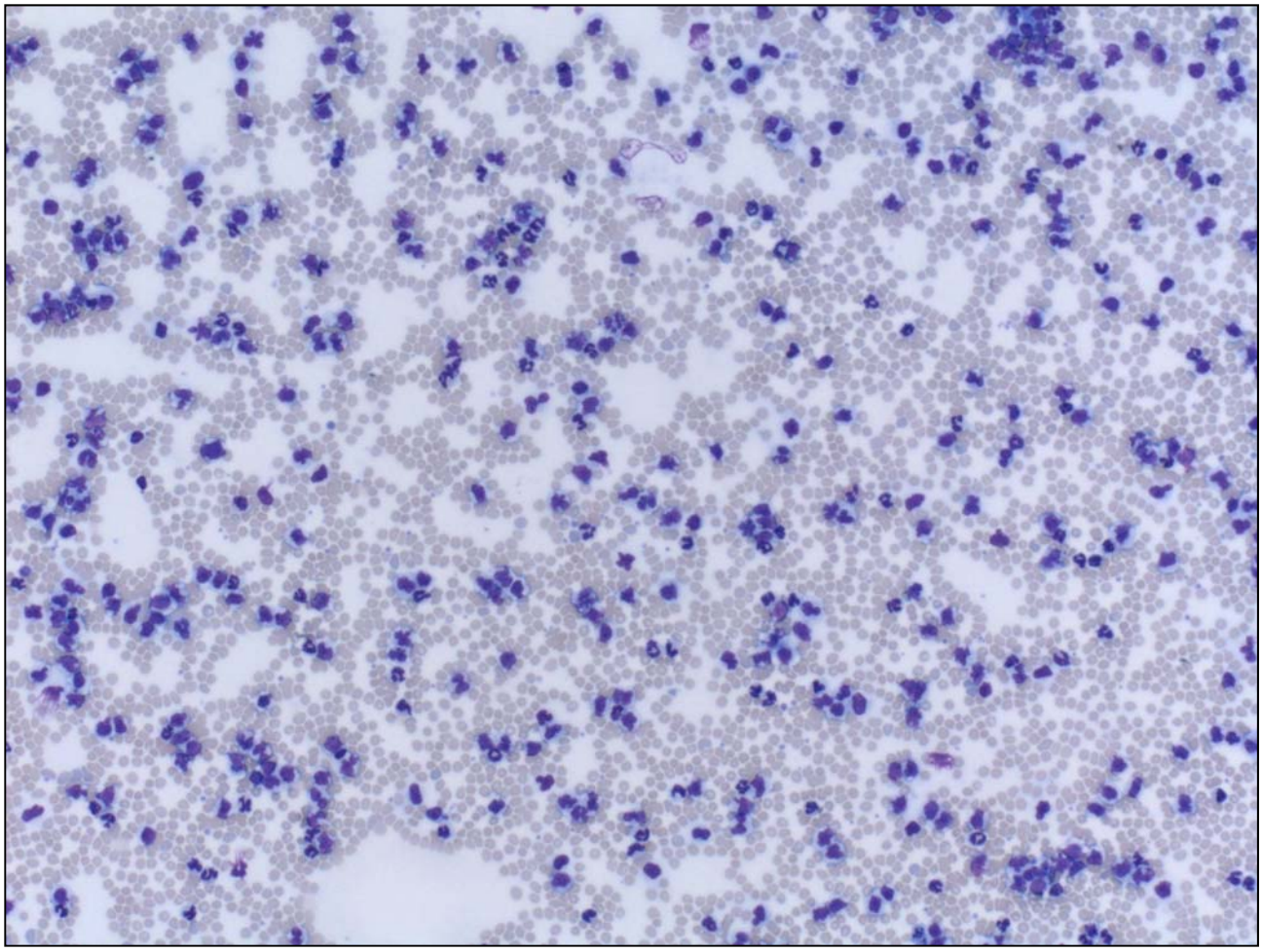

Figure 5: Peripheral blood smear, modified Wright's stain, 100x objective; majority of lymphocytes are large cells, with variably shaped nuclei, inconspicuous nucleoli, abundant cytoplasm and multiple paranuclear azurophilic granules

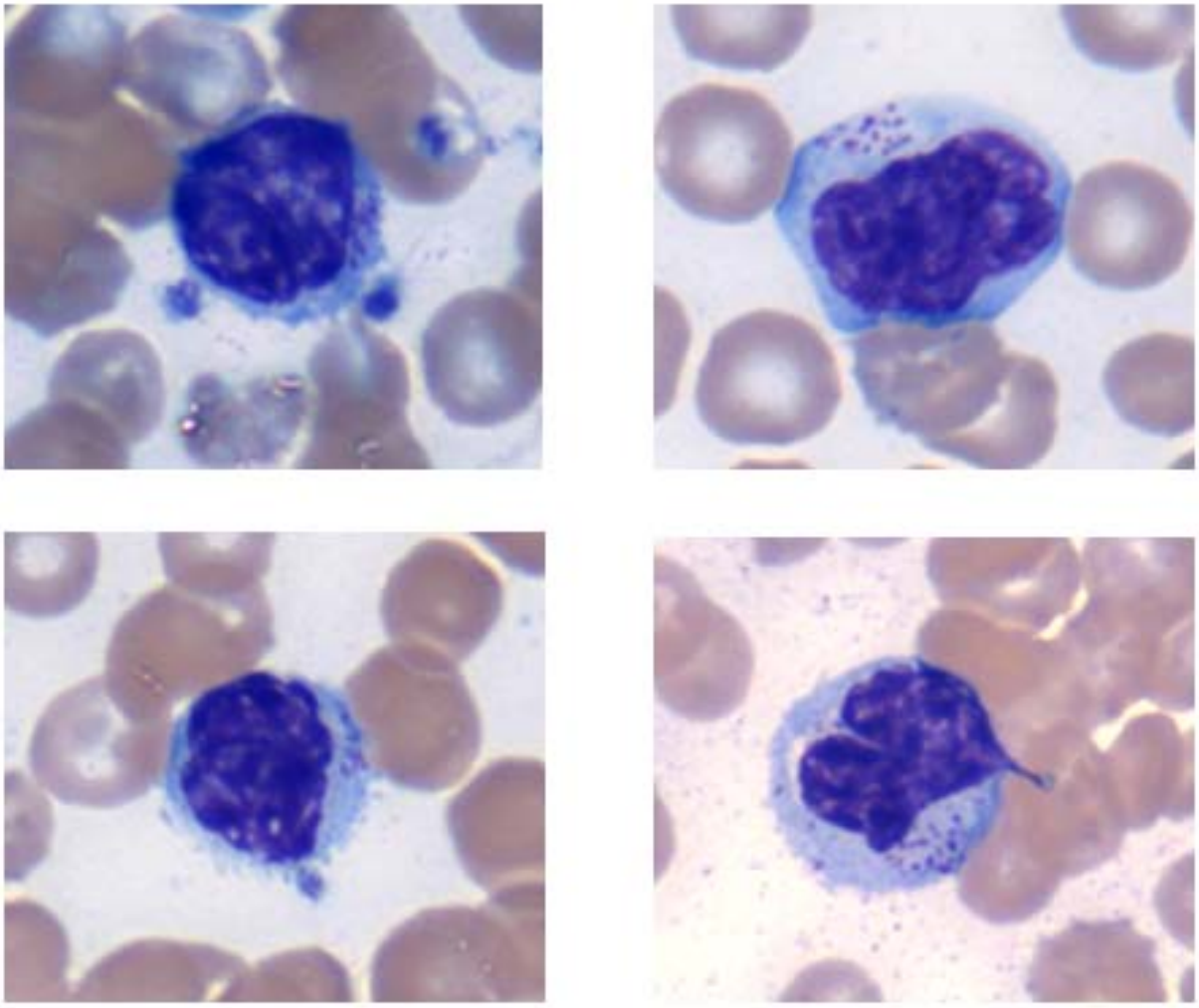

Questions:

What are your differential diagnosis?

What is your explanation for the differences in the reports from the two analyzers?

What other tests would you suggest to do?